

Malfunction of a double-balloon carotid shunt as a result of herniation of the proximal balloon

John F. Eidt, MD, Mark B. Kahn, MD, Gary W. Barone, MD, James M. Cook, MD, and Robert W. Barnes, MD, *Little Rock, Ark.*

Successful use of a shunt during carotid endarterectomy presupposes the avoidance of known shunt-related complications. We report the failure of a double-balloon intraluminal carotid shunt caused by herniation of the proximal balloon over the end of the shunt resulting in obstruction of blood flow in the shunt. (*J VASC SURG* 1990;12:62-4.)

The use of an indwelling arterial shunt during carotid endarterectomy remains controversial.¹⁻³ Proponents argue that a functioning shunt minimizes the risk of cerebral hypoperfusion during carotid endarterectomy, and that complications from the use of intraluminal shunts rarely occur.² Other surgeons have speculated that hypoperfusion is seldom a cause of perioperative stroke, and that some complications directly related to the use of shunts go unrecognized.^{4,5} We report a case of the malfunction of a double-balloon carotid shunt caused by herniation of the proximal balloon resulting in obstruction of blood flow in the shunt.

CASE REPORT

The patient was a 70-year-old man admitted to the John L. McClellan Veterans Administration Medical Center for treatment of left hemispheric transient ischemic attacks. The patient reported three episodes of transient numbness and weakness of the right hand and face during the 6 weeks before admission. He had been taking aspirin for coexistent coronary artery disease. Before operation he had no demonstrable neurologic deficit. A CT scan revealed mild, symmetrical cortical atrophy but no focal infarcts. Duplex Doppler examination demonstrated a high-grade stenosis at the origin of the left internal carotid artery. Angiography confirmed a tight stenosis in the left internal carotid artery at the bifurcation. Minimal disease existed in the siphon region of the left internal carotid artery, and the right carotid artery was mildly diseased.

With the patient under general anesthesia, the left carotid artery bifurcation was exposed and controlled with

vessel loops. After heparin was administered (5000 units), an arteriotomy was made in the common carotid artery and extended 2 cm into the internal carotid artery. Back-bleeding was noted from the internal carotid artery, although it was not brisk. It was elected to use an Inahara-Pruitt T-shunt (Model 400-40, Ideas For Medicine, Tampa, Fla.) (Fig. 1). This shunt is designed to be held in place by latex balloons inflated in the common and internal carotid arteries and does not require external clamps. The shunt is equipped with a sideport that can be used to measure blood pressure and monitor flow. The distal end of the catheter was easily inserted into the internal carotid artery, and the balloon was inflated with 0.25 ml normal saline. The proximal end of the shunt was then inserted into the common carotid artery without difficulty and the balloon inflated with sufficient normal saline (1.5 ml) to stop the flow of blood around the balloon according to the manufacturer's guidelines. The sideport was opened and back-bleeding verified from the internal carotid artery and from the common carotid artery. Flow in the shunt was further verified with a hand-held Doppler (10 mHz).

The endarterectomy was carried out in standard fashion. Approximately 10 minutes into the endarterectomy we noticed that blood had layered in the shunt, and that there was no detectable flow by Doppler. The sideport was opened, which confirmed back-bleeding from the internal carotid artery, but there was no inflow from the common carotid artery. The proximal end of the shunt was adjusted slightly, which immediately resulted in the return of brisk flow. We proceeded with the endarterectomy only to be interrupted approximately 5 minutes later by the same problem. Again, flow was restored by slightly repositioning of the proximal end of the shunt. The endarterectomy was finished, and the patient recovered without evidence of neurologic injury.

Laboratory evaluation

We examined the shunt in the laboratory by inflating the proximal balloon of the shunt inside

From the Department of Surgery, University of Arkansas for Medical Sciences.

Reprint requests: John F. Eidt, MD, Dept. of Surgery, Slot 520, University of Arkansas for Medical Sciences, 4301 West Markham, Little Rock, AR 72205
24/1/18653

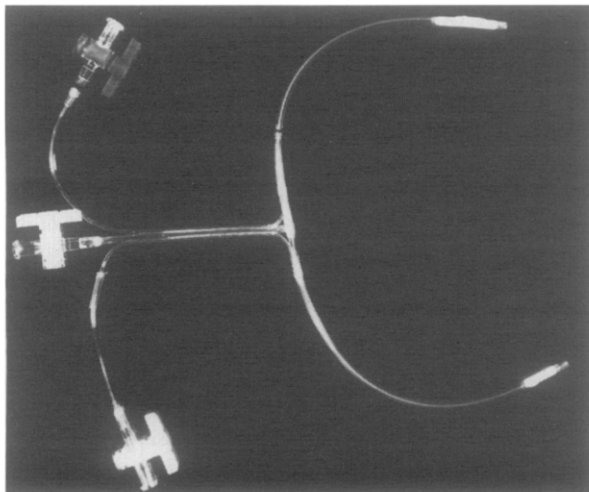


Fig. 1. The Pruitt-Inahara (Model 400-40) carotid shunt is a No. 9F, 33 cm long polyvinyl tube with inflatable latex rubber balloons located at each end, which retain the shunt within the vessel. External clamps are not necessary. A sideport allows access to the arterial circulation for monitoring blood pressure and aspiration.

simulated blood vessel (Fig. 2). During inflation the proximal balloon herniated over the end of the catheter and completely obstructed the lumen. Slight manipulation could easily relieve the obstruction.

DISCUSSION

Fundamental to arguments in favor of routine shunting during carotid endarterectomy is the premise that the shunt itself does not cause specific complications in most cases. Complications related to shunt use have been reported infrequently in recent surgical series.^{1,6,7} Despite the apparent rarity, reported complications from the use of a variety of different types of shunts include subintimal dissection,⁸ rupture of the internal carotid artery,⁹ migration of the shunt, embolization of fragile atherosclerotic debris,¹⁰ and thrombosis.¹⁰ In the current case herniation of the proximal occlusion balloon of a double-balloon intraluminal carotid shunt resulted in obstruction to blood flow in the shunt.

We continue to selectively use the double-balloon shunt during carotid endarterectomy. Particularly in cases of a high carotid bifurcation or when extra internal carotid exposure is needed we have found that external clamps can obscure the distal end point of dissection. Gentle traction can be placed on the internal carotid artery often gaining a valuable few millimeters. The shunt should be inserted carefully into the carotid arteries to avoid intimal injuries. Overinflation of the balloon should be avoided. The

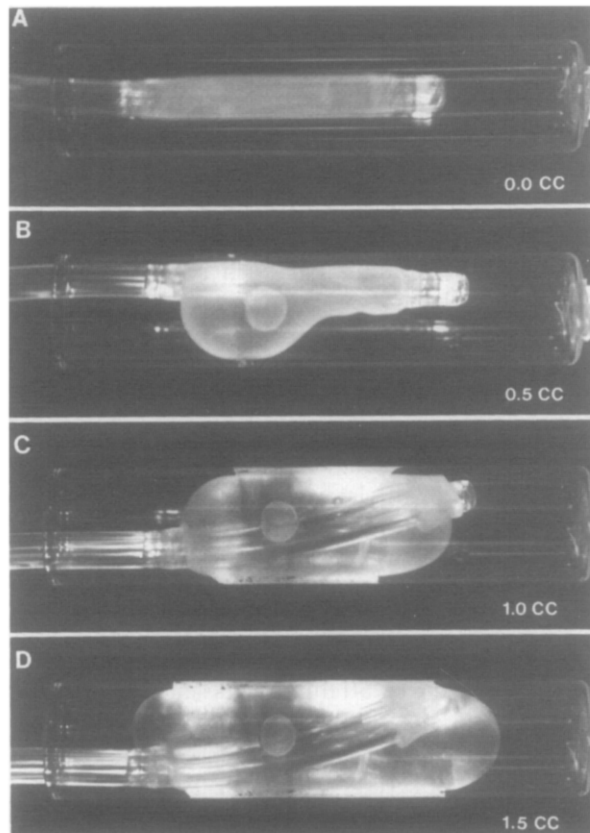


Fig. 2. Series of photographs taken during inflation of the proximal balloon of a double-balloon carotid shunt. The balloon has been placed inside a glass tube with an internal diameter of 8 mm to approximate the internal diameter of a normal common carotid artery. With sequential inflation the balloon herniates over the end (D) of the proximal catheter, thus obstructing blood flow.

balloons should be inflated slowly until the catheter is properly seated in the lumen of the artery. It is important to verify that the shunt is functioning properly after it is in position. A variety of techniques have been described to verify pulsatile blood flow in shunts including the use of an intraoperative Doppler transducer,¹¹ intraoperative supraorbital oculoplethysmography,¹² and specially designed in-line flow probes.¹³ We have used the hand-held Doppler because of its nearly universal availability and ease of use.

A variety of unique safety features have been incorporated into the design of the Inahara-Pruitt shunt to minimize the risks associated with its use. The ends of the shunt are polished and rounded to reduce the risk of intimal injury or dissection. The distal balloon system contains a safety valve that effectively prevents overinflation of the balloon. The T-port allows easy access to the arterial circulation

for measurement of pressure and verifying back-bleeding. The shunt is pliable and easily manipulated during endarterectomy. The balloons are made of soft, latex rubber that inflate with relatively little resistance. The internal balloons obviate the need for external clamps or tourniquets, which may injure the vessel and obscure visualization of the end of the endarterectomy. The use of other types of double-balloon carotid shunts has been reported, but we have no first-hand experience with them.¹⁴⁻¹⁶

It should be noted that natural latex is a relatively delicate elastomer.¹⁷ It can be altered by ionizing radiation, direct sunlight, ozone, extremes of temperature, and other chemical and physical stresses.¹⁷ The expiration date on the product indicates the shelf life (3 years) of the latex used in the balloons. Re-sterilization is not recommended. It is important to pretest each balloon for leaks before use and to verify uniform inflation. Care should be taken to avoid overinflation as this may lead to vessel rupture or herniation of the balloon. The manufacturer recommends 1.25 to 1.50 ml normal saline in the proximal balloon, and this should not be exceeded. Finally, once in position, flow should be verified through one of several techniques.

This case report illustrates the failure of a double-balloon intraluminal carotid shunt caused by herniation of the proximal balloon resulting in obstruction of flow in the shunt. Techniques outlining the safe use of the Inahara-Pruitt intraluminal shunt are reviewed.

REFERENCES

1. Sundt TM Jr, Ebersold MJ, Sharbrough W, Piepgras DG, Marsh WR, Messick JM Jr. The risk-benefit ratio of intra-operative shunting during carotid shunting. *Ann Surg* 1986; 203:196-204.
2. Javid H, Julian OC, Dye WS, et al. Seventeen-year experience with routine shunting in carotid artery surgery. *World J Surg* 1979;319:167-77.
3. Ferguson GG. Intra-operative monitoring and internal shunts: are they necessary in carotid endarterectomy. *Stroke* 1982;13:287-9.
4. Sundt TM Jr. The ischemic tolerance of neural tissue and the need for monitoring and selective shunting during carotid endarterectomy. *Stroke* 1983;14:93-8.
5. Bandyk DF, Thiele BL. Safe intraluminal shunting during carotid endarterectomy. *Surgery* 1983;93:260-3.
6. Hertzner NR, Beven EG. A retrospective comparison of the use of shunts during carotid endarterectomy. *Surg Gynecol Obstet* 1980;151:81-4.
7. Browse NL, Ross-Russell R. Carotid endarterectomy and the Javid shunt: the early results of 215 consecutive operations for transient ischaemic attacks. *Brit J Surg* 1984;71:53-7.
8. Loftus CM, Dyste GN, Reinartz SJ, Hingtgen WL. Distal cervical carotid dissection after carotid endarterectomy: a complication of indwelling shunt?. *Neurosurgery* 1986;19: 441-5.
9. Mukherjee D, Inahara T. Another use of the shunt in vascular surgery. *Am J Surg* 1983;146:385-6.
10. Beezley MJ. Safer shunt insertion during carotid endarterectomy. *J VASC SURG* 1985;2:607-9.
11. Seifert K, Blackshear W. Continuous-wave Doppler in the intraoperative assessment of carotid endarterectomy. *J VASC SURG* 1985;2:817-20.
12. Pearce HJ, Becchetti JJ, Brown HJ. Supraorbital photoplethysmographic monitoring during carotid endarterectomy with the use of an internal shunt: an added dimension of safety. *Surgery* 1980;87:339-42.
13. Miller BV, Loftus CM, Hiratzka LF, Laughlin DE. Technical note: in vitro evaluation of an in-line Doppler flow-meter system for carotid artery shunts. *Neurosurgery* 1988;22:608-12.
14. Brener BJ, Brief DK, Alpert J, Parsonnet V. A T-shaped carotid shunt. *Arch Surg* 1975;110:1249-50.
15. Furui T, Hasuo M. Indwelling double-balloon shunt for carotid endarterectomy. *J Neurosurg* 1984;60:861-3.
16. Hodge J. The use of intraluminal intravascular balloon occlusive shunts in vascular surgery. *Am J Surg* 1979;137: 278-9.
17. St.Cyr DR. Natural rubber. In: Grayson M, ed. *Encyclopedia of chemical technology*. 3rd ed. New York: John Wiley & Sons, 1982:468-91.