

# Poor durability of carotid angioplasty and stenting for treatment of recurrent artery stenosis after carotid endarterectomy: An institutional experience

André R. Leger, MD,<sup>a,b</sup> Michael Neale, FRACS,<sup>b</sup> and John P. Harris, FRACS,<sup>c</sup> *Portland, Ore, and Sydney, Australia*

**Purpose:** Recurrent stenosis after carotid endarterectomy (CEA) is often regarded as an optimal application of carotid artery angioplasty and stenting (CAS). The extended durability of CAS for recurrent carotid artery stenosis after CEA is unknown. We present the intermediate-term surveillance results for all eight CAS procedures performed over a 28-month period at a single tertiary referral center.

**Methods:** Patients had recurrent carotid stenosis after CEA, whether symptomatic or asymptomatic, of 80% to 99% stenosis on preprocedural carotid duplex scan examination. Uncovered, self-expanding metal stents, in conjunction with angioplasty, were used in all patients. Baseline and scheduled interval follow-up duplex ultrasound scan was used to assess intrastent restenosis. Further angiography was reserved for those patients obtaining additional intervention.

**Results:** One transient ischemic attack was observed 1 day after the procedure, and no cerebral infarcts occurred. All patients had angiographic resolution of the stenosis and postprocedural duplex scan studies without residual stenosis. Subsequent interval surveillance duplex scan examinations revealed significant (60%-79%) to critical (80%-99%) recurrent stenosis in six (75%) of eight patients, two of whom went on to further interventions. Of those with intrastent restenosis, four (75%) progressed to critical (80%-99%) stenosis. Mean follow-up was 20.2 months (range, 12-37 months). The two lesions that have not yet shown restenosis are those with the shortest follow-up interval, each at 12 months.

**Conclusions:** In contrast to the optimistic claims in other series, this limited series suggests that angioplasty with stenting for recurrent carotid artery occlusive disease after CEA, although relatively safe in the short term, has significant limitations in terms of durability of results. (*J Vasc Surg* 2001;33:1008-14.)

Endovascular interventions have become increasingly popular in the treatment of occlusive peripheral vascular disease. This has been largely driven, over the last two decades, by advances in technology including improved interventional catheters, improved contrast media, refinement of angiography hardware and software, and, most recently, the broad application of endovascular stents. Balloon angioplasty and stenting have achieved an accepted place in the treatment of aortoiliac occlusive disease. Long-term results for infrainguinal interventions have been less satisfactory<sup>1</sup> but have become common in many centers worldwide for symptomatic relief and for the delay of initial operative intervention. The earliest case citing the use of angioplasty in the carotid artery was for a symptomatic fibromuscular dysplasia lesion dilated in 1980.<sup>2</sup> Expectations of a rapid dissemination of this technique and its more recent incarnation, combined carotid angioplasty and stenting (CAS), have been slower than that of other endovascular applications to materialize.

The proposed benefit of CAS in carotid artery stenosis depends largely on the extrapolation of benefits from open endarterectomy. Large, randomized, controlled studies have provided support for open carotid endarterectomy (CEA) for patients both with and without symptoms with high-grade stenosis and for patients with symptoms who have moderate stenosis.<sup>3-6</sup> However, the benefit of CEA over medical treatment depends on an acceptably low perioperative stroke and death rate. The incidence of procedure-related stroke and death must remain at or less than 6% in patients with symptoms and 3% in symptom-free patients to recognize a benefit over 5 years.<sup>7</sup> As recently as 1993, the risk of serious neurologic complications from diagnostic cerebral angiography in symptomatic carotid disease was found to be 2%.<sup>8</sup> However, many centers anecdotically claim a lower incidence, particularly for routine diagnostic studies. The passage of wires and devices beyond carotid lesions presents a unique risk in the cerebral circulation. This risk is not yet well quantified and is likely dependent on the type of lesion, the physician performing the procedure, and the device. Several nonrandomized series of CAS procedures for carotid stenosis have been published demonstrating that in carefully selected patients, the procedure can be performed with acceptable short-term complication rates.<sup>9,10</sup> Although widespread catastrophic angiographic complications have seemingly not manifested, the one published randomized study of CAS versus endarterectomy in patients with symptoms was halted after early analysis showed a statistically significant higher stroke rate in those undergoing CAS.<sup>11</sup>

From the Oregon Health Sciences University,<sup>a</sup> the Royal Prince Alfred Hospital,<sup>b</sup> and the Department of Surgery, University of Sydney.<sup>c</sup>

Competition of interest: nil.

Reprint requests: John P. Harris, Room 401, Blackburn Building D06, University of Sydney NSW 2006 (e-mail: j\_harris@surgery.usydney.edu.au).

Copyright © 2001 by The Society for Vascular Surgery and The American Association for Vascular Surgery.

0741-5214/2001/33:1008-14

doi:10.1067/mva.2001.113485

Table I. Patient characteristics and outcomes

Patient (age [y], sex)	Time since CEA	Symptomatic (yes/no)	Favorable angiographic outcome (yes/no)	Restenosis after carotid stenting (yes/no) with time interval if yes	Outcome	Length of follow-up
1 (60, f)	10 mo	No	Yes	Yes, 6 mo	Asymptomatic and stabilized at 80%-99% stenosis	24 mo
2 (77, f)	6 mo	Yes	Yes	Yes, 12 mo	Asymptomatic and stabilized at 80%-99% stenosis	37 mo
3 (58, f)	11 mo	No*	Yes	No	Disease free	12 mo
4 (61, m)†	48 mo	Yes	Yes	Yes	60%-80% stenosis at isolated 26-mo examination	26 mo
5 (54, f)	18 mo	No	Yes	Yes, 11 mo	Symptomatic 80%-99%, stent-ligated, CCA-ICA bypass graft	12 mo followed by intervention‡
6 (60, m)§	8 mo	No	Yes	Yes, 12 mo	Asymptomatic and stabilized at 60%-80%	18 mo, no change in 6 mo
7 (59, m)	4 mo	No	Yes	Yes, 6 mo	Asymptomatic 80%-99% restenosis, electively excised and bypassed	6 mo, followed by intervention‡
8 (73, m)	11 y	No	Yes	No	Disease free	12 mo

\*Global ischemic symptoms not attributable to carotid distribution.

†Initially lost to follow-up, no scans from 3 to 26 months.

‡Follow-up has continued on these patients since their interventions, and total follow-up time for these patients has been calculated for these patients from time of stent placement. Length of follow-up used to calculate mean is 21 and 15 months, respectively, for patients 5 and 7.

§TIA after the procedure on day 3. Anticoagulated with no additional episodes.

CCA, Common carotid artery; CEA, carotid endarterectomy; ICA, internal carotid artery; TIA, transient ischemic attack.

Recurrent carotid artery stenosis, particularly that attributed to myointimal hyperplasia (MIH), has been suggested as an optimal application for CAS.<sup>12,13</sup> The rationale behind this has been twofold. First, reoperative carotid surgery carries a higher risk of associated technical complications including cranial nerve damage and problems with wound healing. Second, the smooth nature of the MIH lesion makes it appear much less prone to embolic sequelae of endoluminal manipulation. This is balanced with the relatively benign natural history of recurrent carotid stenosis and the lack of clear data on which to base operative indications.<sup>14,15</sup> However, O'Donnell et al<sup>16</sup> did show up to a 7.5% unheralded stroke rate in high-grade (> 75%) recurrent stenosis managed nonoperatively compared with 2.1% in their operative arm. This has led to some enthusiasm for treatment of higher grades of asymptomatic recurrent stenosis.

The aim of this series evaluation was to document the long-term incidence of intrastent restenosis after CAS in recurrent carotid stenosis after CEA. This institutional experience is contrasted with other published reports in comparable patient populations.

## METHODS

Between April 1996 and August 1998, eight patients with recurrent carotid artery stenosis received CAS at Royal Prince Alfred Hospital in Sydney, Australia. There were four men and four women with a mean age of 62 and 62.5 years, respectively. Mean elapsed time since endarterectomy was 29 months with a range of 4 months to 11 years (15 months if the 11-year outlier is excluded). Three patients had symptoms, two with ipsilateral hemispheric transient ischemic attacks (TIAs) and one with

symptoms consistent with global cerebral hypoperfusion not attributable to a specific carotid lesion. The other patients had progressive asymptomatic carotid restenosis. The decision to treat asymptomatic lesions was based on clinician judgment. However, the decision to offer CAS over standard operative therapy was based on a higher than usual risk of operative complications, unacceptable anesthetic risk, or patient unwillingness to undergo repeat endarterectomy. The procedure was offered, and informed consent was obtained after a consensus was established about the appropriateness of therapy in a joint vascular surgery and radiology forum. All patients received a self-expanding WallStent (Schneider, Minneapolis, Minn), and all procedures were performed in an interventional radiology suite by an experienced interventional radiologist. Lesions received balloon angioplasty before and after stent deployment. No consistent anticoagulation protocol was maintained. Patients with symptoms received intravenous heparin while awaiting the procedure and for 12 hours after the sheaths were removed. All patients were given aspirin before stent placement and continued taking aspirin afterward unless they were also receiving warfarin. Duplex ultrasound scan was performed on all patients before discharge from the hospital and at 3, 6, and 12 months postprocedurally and annually thereafter. The modified Zwiebel classification was used to grade degrees of internal carotid stenosis.<sup>17</sup> Lesions received balloon angioplasty before and after stent deployment. An indexed stenosis of 60% to 80% was regarded as significant, and 80% to 99% was regarded as critical. Repeat angiography was performed only on those patients in whom an additional intervention was planned. More frequent studies were ordered on the basis of symptoms or the detection of

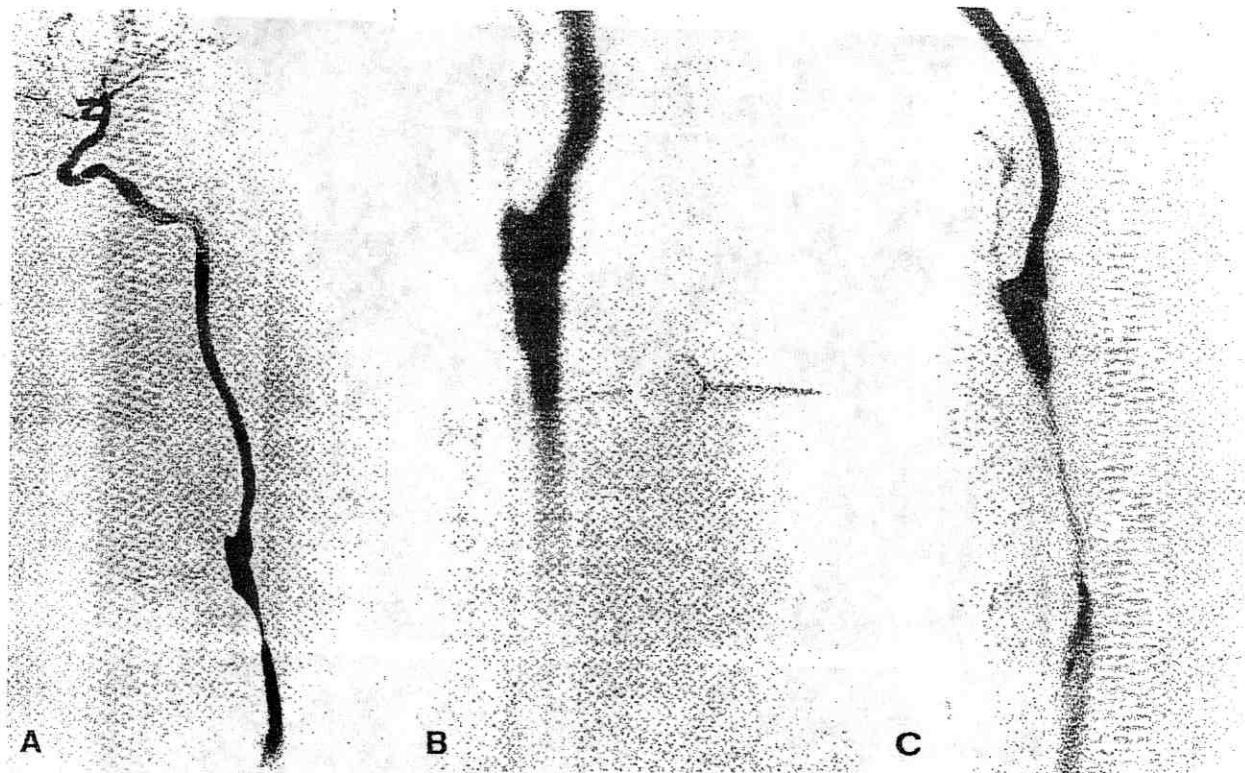


Fig 1. Illustrative angiograms. \* A, Preprocedural angiogram on patient with recurrent carotid stenosis after endarterectomy with vein patch repair (patient 7 from Table I). B, Poststent placement angiogram in same patient. C, Same patient with severe recurrent intrastent stenosis before intervention. \*Angiographic determination of stenosis > 80%, views selected for best consistent view of stenosis, stent and recurrence from same view.

new or progressive recurrent stenosis. One patient was initially lost to follow-up after his 3-month scan and received his next duplex scan evaluation at 26 months. Patient specifics and outcomes are summarized in Table I.

## RESULTS

All stents were placed without immediate neurologic or angiographic complications. No episodes of hemodynamic instability were recorded. One patient had a single TIA in the distribution of the stented carotid and was given warfarin (overlapping with heparin) with no further events. A second patient was treated postoperatively with warfarin at the discretion of the surgeon. Complete resolution of luminal stenosis was seen on angiogram after stent deployment in all cases. Fig 1 is a series of illustrative angiograms: before the procedure, after the procedure, and with recurrent intrastent stenosis, in a patient with recurrent carotid stenosis after internal carotid artery endarterectomy with vein patch repair. Duplex ultrasound scan performed before discharge revealed no residual stenosis in any patients. At 3 months a duplex scan evaluation revealed > 60% intrastent restenosis in one (12.5%) of eight patients. Six-month examinations

revealed three (37.5%) of eight patients with intrastent restenosis > 60%, one of which was > 80% (12.5%). By 1 year, five (62.5%) of eight had restenosis > 60%, with three (37.5%) > 80%. Of the six patients with follow-up of 26 months or longer, all (100%) had restenosis > 60%, and four of the six restenoses were > 80%. The two patients (25%) without current evidence of intrastent restenosis are those with the shortest interval follow-up; each was 1 year. Fig 2 is representative of a postprocedural duplex scan evaluation of a stent along with a follow-up duplex scan in the same patient showing intrastent restenosis. Common carotid artery to internal carotid artery bypass graft with a polytetrafluoroethylene graft was performed in two patients (25%). One of these patients had the stent removed, and the other had it ligated in situ. The first was undertaken when a critically stenosed lesion became symptomatic 11 months after placement, and the second was undertaken electively when the 6-month scan progressed to critical stenosis. With a mean follow-up of 21 months, all patients are alive, and none have experienced a new neurologic event beyond those cited. Those remaining with asymptomatic stenosis are currently being treated expectantly.



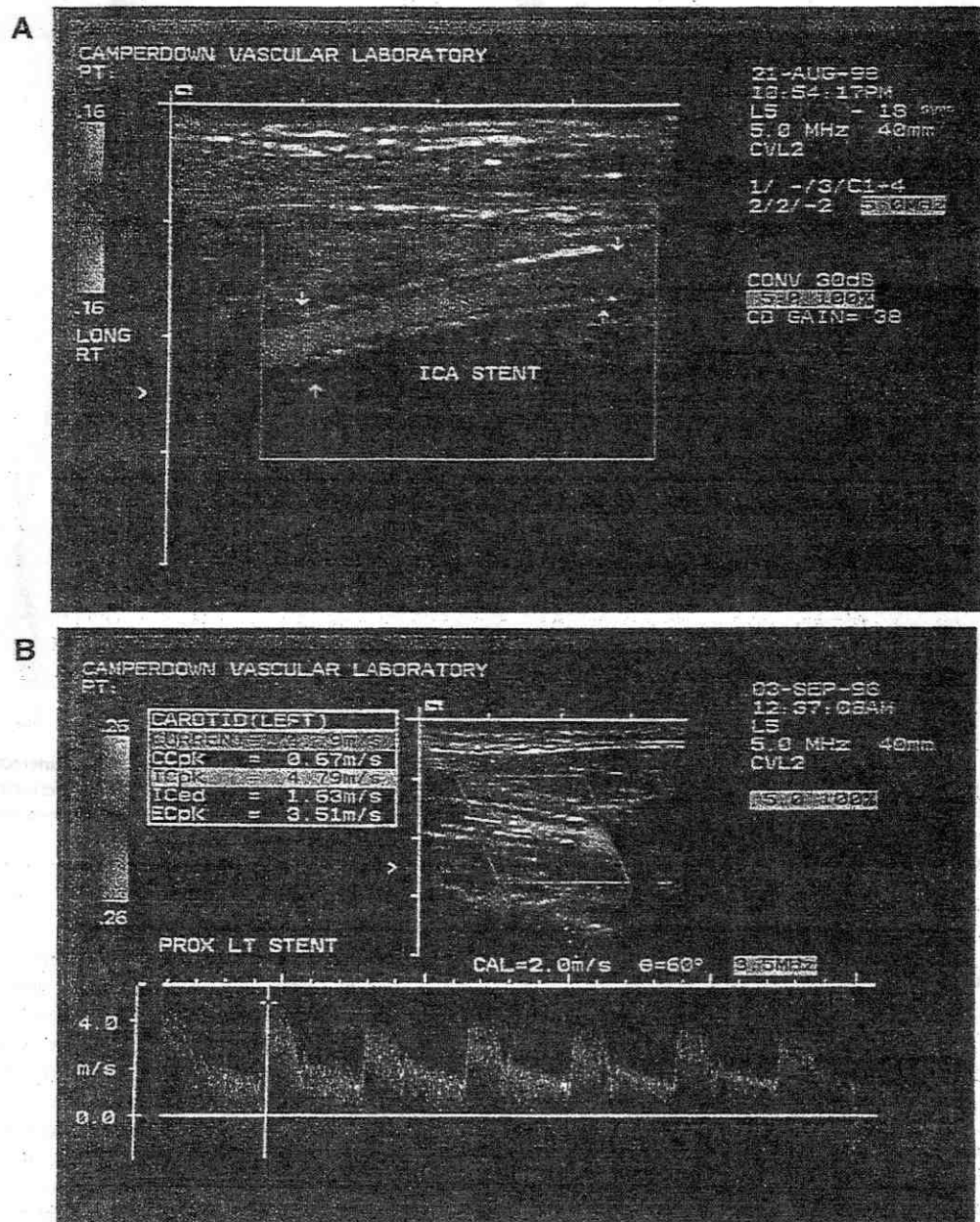


Fig 2. Illustrative duplex scan evaluation of carotid stenting. A, Immediate poststent placement (patient 5 from Table I). B, Follow-up duplex showing critical intrastent stenosis.

## DISCUSSION

Recurrent carotid stenosis after endarterectomy remains somewhat of a therapeutic conundrum. Reports of its incidence vary widely depending on the length of follow-up and criteria for determining and defining restenosis but range from 4% to 19%.<sup>15,18</sup> The characteristics and the morbidity of recurrent lesions may also vary widely depending on the pathologic condition pre-

sent in the lesion. MIH lesions are those characterized by a proliferation of vascular smooth muscle and matrix deposition and represent an exuberant cellular response to injury or manipulation.<sup>19</sup> Grossly, they tend to be smooth lesions with little embolic potential. Most MIH lesions occur within 6 to 24 months after an arterial intervention. Vessels outside the carotid distribution have shown MIH as a reaction to balloon angioplasty

Table II. Dedicated series of CAS in carotid restenosis

Author	No. of patients in study	No. of patients available for follow-up	Mean follow-up interval	Method of follow-up evaluation	% Restenosis
Hobson	16	16	11 mo	Duplex scan	0
Yadav	22	8	6 mo	Angio	0
Lanzino	18*	13†	16 mo	Duplex scan and angio	7%
RPAH results	8	8	20.2 mo	Duplex scan and selected angio	75%

\*Subset of patients in study who received stents in addition to angioplasty.

†Excludes those who have not reached their initial follow-up interval.

Angio, Angioplasty; CAS, carotid angioplasty and stenting; RPAH, Royal Prince Alfred Hospital.

and stent placement.<sup>1</sup> Recurrent stenosis that develops 3 years after endarterectomy is nearly always found to be atherosclerotic in nature. Recurrent atherosclerotic disease, like its nonrecurrent predecessor, tends to produce more delicate, friable lesions that are more likely to show intraplaque hemorrhage, ulcerate, or form emboli.

This series of patients presented here likely represents a mixture of pathology. Unfortunately, with endoluminal interventions, no specimen for pathology is available. If it is accepted that most lesions occurring more than 36 months after CEA are recurrent atherosclerotic plaques, then six of the eight patients in this group likely represented MIH. Indeed, one of the two patients yet to show recurrent stenosis is the outlier of 11 years since CEA and is likely to represent a different pathologic condition. This high incidence of early intrastent recurrence of carotid stenosis is concerning. It may become apparent that the very lesion that appears most attractive for endovascular intervention is the one most resistant to it.

Case reports and small series dedicated to angioplasty alone as well with stenting in the treatment of recurrent carotid stenosis after CEA have accumulated through the 1990s. In 1993, Lorenzi et al<sup>20</sup> published a case report of the intraoperative use of angioplasty alone for recurrent CEA with satisfactory short-term results. In 1996, Bergeron et al<sup>16</sup> published a series of angioplasty alone in recurrent stenosis after CEA with a high complication rate. Here, stenting was introduced as a rescue maneuver in three of the 15 patients. One of these patients had an early death, and the other two had acceptable results at 18 and 48 months. The three previously published series where CAS was evaluated as the primary treatment modality in recurrent carotid stenosis after endarterectomy seemed to support the short-term safety and feasibility of the procedure. Durability of results is less well documented. Table II summarizes relevant published series where CAS was the primary treatment mode in recurrent carotid stenosis. Hobson et al<sup>21</sup> published a dedicated series of 16 cases of CAS for recurrent carotid stenosis comparing them with internal historic controls. All patients were less than 36 months from CEA. No adverse neurologic outcomes were encountered, and there was no report of significant restenosis at a mean follow-up of 11 months as assessed with duplex ultrasound scan. The mean surveillance was relatively short, because durability of the repair was not the specific outcome being

investigated. Yadav et al<sup>23</sup> also report a series of 22 patients mainly with symptoms who were treated with CAS. Most of these patients (64%) presented more than 36 months since CEA. Complications included one minor stroke (4%), one groin hematoma, and one patient undergoing an external carotid artery to internal carotid artery bypass graft resulting from contralateral carotid occlusion. The study end point was repeat angiography at 6 months after CAS. Only eight (37.5%) of 22 subjects returned for the follow-up, none of whom showed significant intrastent restenosis. Most recently, Lanzino et al<sup>12</sup> published a mixed series of carotid angioplasty with and without stenting for recurrent carotid stenosis in 21 patients. Neurologic and angiographic complications were low compared with other series. For follow-up results, five (24%) of 21 patients were not included because they had not yet reached their initial 6-month evaluation. Of the remaining 16 patients, five underwent angioplasty alone, two of whom ultimately converted to CAS. Thus, 13 patients actually received CAS, and recalculated intervals from the date of the stenting yielded a mean clinical follow-up of 16 months (range, 6-36 months) and a mean follow-up with objective testing for recurrent stenosis of 13 months (range, 6-34 months). Six (46%) of this subset of 13 patients had symptoms before the CAS procedure, but no neurologic symptoms attributable to treated carotids were encountered in follow-up. One patient died of nonvascular causes. Duplex ultrasound scan was used as a postprocedural screening tool. No quantitative value for in-stent restenosis was assigned from the duplex scan evaluations; only increased velocities were noted. Four (30%) of 13 patients appeared to have this finding. Subsequent angiograms on these patients revealed only one significant (55%) stenosis, and the rest were mild to moderate according to criteria by the North American Symptomatic Carotid Endarterectomy Trial (NASCET). Of the 13 patients who received CAS and were available for follow-up studies, four (30%) had an interval longer than 36 months since CEA. These limited data qualifying CAS in recurrent carotid stenosis are the bulk of the published data on which recommendations stand.

Beyond limited numbers of patients and heterogeneous lesions, even criteria for quantifying intrastent recurrent stenosis remain a challenge. Although angiograms remain the gold standard from which the NASCET recommendations and those arising from the interventional

Table III. Zwiebel Doppler spectrum analysis for grading carotid stenosis<sup>17</sup>

Diameter stenosis (%)	Peak systolic velocity (cm/s)	End-diastolic velocity (cm/s)	Systolic velocity ratio (VICA:VCCA)	Diastolic velocity ratio (VICA:VCCA)	Spectral broadening (cm/s)
0	< 110	< 40	< 1.8	< 2.4	< 30
1-39	< 110	< 40	< 1.8	< 2.4	< 40
40-59	< 130	< 40	< 1.8	< 2.4	< 40
60-79	> 130	> 40	> 1.8	> 2.4	> 40
80-99	> 250	> 100	> 3.7	> 5.5	> 80

VCCA, Velocity of common carotid artery; VICA, velocity of internal carotid artery.

arm of the Asymptomatic Carotid Atherosclerosis Study recommendations arise, it is now difficult to justify liberal application of routine carotid angiograms, particularly for asymptomatic follow-up. Duplex ultrasound scan for evaluation of intrastent restenosis is in evolution. Robbin et al<sup>23</sup> attempted to assess its adequacy prospectively by comparing several of the duplex scan criteria used to quantify stenosis with angiograms. The results were promising. However, an unusually low incidence of intrastent recurrence (1 of 65 patients at 6-month follow-up) limits the ability to liberally extrapolate their findings. The stents themselves appeared to give no interference; however, some unique aspects of stents, particularly long intrastent stenosis and sharp transition of flow into the stent, may present technical interference with some criteria systems. Specifically, the sharp transition from normal lumen to fixed stent diameter, particularly if the stent extends into the common carotid artery, could accentuate the systolic and diastolic velocity ratios and accentuate a stenosis (Table III). Additionally, long stenosis, as might be encountered over the length of a stent, could interfere with poststenotic spectral broadening by extending it higher in the neck or tapering out the turbulence more smoothly than is found with native stenosis.

## CONCLUSIONS

The debate about the role of CAS in both primary and recurrent carotid stenosis is likely to escalate given the pace of technologic advances in endoluminal equipment, particularly regarding cerebral protection devices. However, the development of indications will require a basis not only in feasibility but also in long-term outcomes. This is a small series; however, the high incidence of restenosis lends a cautionary note to what has been seen as an ideal lesion. Other published series of CAS in the recurrent carotid stenosis do not answer the question of the durability of result. All six patients in this series who were followed up for more than 24 months showed significant (> 60%) intrastent restenosis. Reviewing other series, we found no single technical variable responsible for the difference in outcomes for patients from this institution. Given the history of MIH and intrastent recurrent disease in other vascular distributions, CAS for recurrent carotid stenosis may well prove to have a relatively minor role in the management of this condition. As the develop-

ment of randomized controlled studies becomes more difficult, the need to establish cooperative databases and uniform outcome criteria in novel treatments is highlighted. In this institution, no blanket policy or protocol dictates treatment strategy for recurrent carotid artery stenosis after endarterectomy. However, in light of local experience, a strong cultural shift away from the use of CAS in this setting has taken place. Given the results of this group of eight patients, it is difficult to support the use of CAS as a routine alternative to open endarterectomy for recurrent carotid stenosis.

## REFERENCES

- Cirit DF, Dalsing MC. Lower-extremity arterial endovascular stenting. *Surg Clin North Am* 1998;78:593-616.
- Garrido E, Montoya J. Transluminal dilation of the internal carotid artery in fibromuscular dysplasia: a preliminary report. *Surg Neurol* 1981;16:469-71.
- European Carotid Surgery Trialist Collaborative Group. MRC European Carotid Surgery Trial: interim results for symptomatic patients with severe (70-90%) or with mild (0-29%) carotid stenosis. *Lancet* 1991; 337:1235-43.
- North American Symptomatic Carotid Endarterectomy Trial Collaborators. Beneficial effect of carotid endarterectomy in symptomatic patients with high-grade stenosis. *N Engl J Med* 1991;325:445-53.
- ECACAS: Endarterectomy for asymptomatic carotid artery stenosis. *JAMA* 1995;273:1421-8.
- Barnett HJ, Taylor DW, Eliasziw M, Fox AJ, Ferguson GG, Haynes RB, et al. Benefit of carotid endarterectomy in patients with symptomatic moderate or severe stenosis. North American Symptomatic Carotid Endarterectomy Trial Collaborators. *N Engl J Med* 1998;339:1415-25.
- Guidelines for carotid endarterectomy: a multidisciplinary statement from the ad hoc Committee, American Heart Association. *Stroke* 1995;26: 188-201.
- Davies KN, Humphry PR. Complications of cerebral angiography in patients with symptomatic carotid territory ischaemia screened by carotid ultrasound. *J Neurol Neurosurg Psychiatry* 1993;56:967-72.
- Criado JC, Wellons E, Clark NS. Evolving indications for and early results of carotid artery stenting. *Am J Surg* 1997;174:111-4.
- Riggs PN, Dewese JA. Carotid endarterectomy. *Surg Clin North Am* 1998;78:881-99.
- Naylor R, Bolia A, Abbott RJ, Pye IF, Smith J, Lennard N, et al. Randomized study of carotid angioplasty and stenting versus carotid endarterectomy: a stopped trial. *J Vasc Surg* 1998;28:326-34.
- Lanzino G, Mericle RA, Lopes DK, Wkhloo AK, Guterman LR, Hopkins LN. Percutaneous transluminal angioplasty and stent placement for recurrent carotid stenosis. *J Neurosurg* 1999;90:688-94.
- Bergeron P, Chambran P, Benichou H, Alessandri C. Recurrent carotid disease: will stents be an alternative to surgery? *J Endovasc Surg* 1996;3:76-9.

14. Lattimer C, Burnand KG. Recurrent carotid stenosis after carotid endarterectomy. *Br J Surg* 1997;84:1206-19.
15. Healy D, Zierler RE, Nicholls SC, Clowes AW, Primozich JF, Bergelin RO, et al. Long-term follow-up and clinical outcome of carotid restenosis. *J Vasc Surg* 1989;10:662-9.
16. O'Donnell T, Rodriguez A, Fortunato J, Welch H, Mackey W. Management of recurrent carotid stenosis: should asymptomatic lesions be treated surgically? *J Vasc Surg* 1996;24:207-12.
17. Zwiebel WJ. Doppler evaluation of carotid stenosis. In: Zwiebel WJ, editor. *Introduction to vascular ultrasonography*. 3rd ed. Philadelphia: WB Saunders; 1992. p. 123-32.
18. Johnson CA, Tollefson DF, Olsen SB, Anderson CA, McKee-Johnson J. The natural history of early recurrent carotid artery stenosis. *Am J Surg* 1999;177:433-6.
19. Neville RF, Sidaway AN. Myointimal hyperplasia: basic science and clinical considerations. *Semin Vasc Surg* 1998;11:142-8.
20. Lorenzi G, Domanin M, Constantini A, Rolli A, Agrifoglio G. Intraoperative transluminal angioplasty of recurrent carotid stenosis. *J Cardiovasc Surg* 1993;34:163-5.
21. Hobson R, Goldstein JE, Jamil Z, Lee BC, Padberg FT, Hanna AK, et al. Carotid restenosis: operative and endovascular management. *J Vasc Surg* 1999;28:235-8.
22. Yadav J, Roubin GS, King P, Iyer S, Vitek J. Angioplasty and stenting for restenosis after carotid endarterectomy. *Stroke* 1996;28:2075-11.
23. Robbin RL, Lockhart ME, Weber TM, Vitek JJ, Smith JK, Yadav J, et al. Carotid artery stents: early and intermediate follow-up with Doppler US. *Radiology* 1997;205:749-56.

Submitted Aug 22, 2000; accepted Oct 30, 2000.